



PATIENT

Max Calvo

PRESENTING CLINICAL SIGNS

History: Grade II-III/VI heart murmur; no clinical signs. *Sedated with torbugesic for study.

SPECIES

Canine

ECHOCARDIOGRAM FINDINGS

2D, m-mode, color flow and Doppler imaging is available.

Left ventricle: The LV diameter is mildly increased with adequate function. LV wall thicknesses are normal.

BREED

Yorkshire Terrier

Left atrium: The left atrium is moderately dilated.

Mitral valve: The mitral valve is diffusely thickened with no prolapse into the left atrial lumen. Moderate eccentric mitral regurgitation with a normal velocity.

SEX

Male Intact

Aortic valve/Aorta: The aortic valve is normal in morphology and mobility. Normal aortic outflow velocity; laminar flow. No aortic insufficiency.

Right ventricle: Normal right ventricular diameter and morphology indicating no overt evidence of pulmonary arterial hypertension.

AGE

12 years

Right atrium: Normal RA dimension.

Tricuspid valve: The tricuspid valve appears mildly thickened with no tricuspid regurgitation.

WEIGHT

17.2lbs

Pulmonic valve/Pulmonary artery: The pulmonic valve is normal in morphology and mobility. No pulmonic insufficiency. Normal RVOT velocity; laminar flow.

Pericardium/other: No pericardial or pleural effusion noted. No obvious cardiac masses.

Heart rhythm: ECG reveals a sinus rhythm with an average HR of 140bpm.

2-Dimensional Measurements

Ao diam (cm)	1.4
LA diam (cm)	2.5
LA:Ao (Swe)	1.7
IVS thickness (cm)	0.72
LVID diastole (cm)	3.6
PW thickness (cm)	0.71
LVID systole (cm)	2.3
FS (%)	37

Doppler Measurements

PV Vmax (m/s)	0.7
AoV Vmax (m/s)	1.7
MR Vmax (m/s)	6.1
TR Vmax (m/s)	NA
TR PG (mmHg)	NA

INTERPRETED BY

Maggie Machen
Lamy, DVM
DACVIM (Cardiology)

INTERPRETATION OF THE FINDINGS

Chronic degenerative valve disease causing moderate mitral regurgitation. Moderate left atrial enlargement indicates there is relatively low risk for imminent complication, however risk for progression to spontaneous congestive heart failure in the future is elevated. No additional issues are identified.

IMAGING

PERFORMED BY

Pamela Harrigan,
RDCS

HOSPITAL NAME

East Boston Animal
Hospital

Given LA dilation, Pimobendan is recommended as below. Assessment of progression in the future will help predict long term outcome, however prognosis is guarded at this stage (B2).

REFERRING VET

Dr. Chopra

RECOMMENDATIONS

- Institute heart muscle support Pimobendan 0.3mg/kg PO q12h.
- Omega fatty acid supplementation and mild salt restriction may be of some long-term benefit.
- Once on Pimobendan for 3-5 days, anesthetic risk is considered mild if needed. Cardiac protective drug choices (opioid/benzodiazepine premedication, propofol or

INVOICE

23842

DATE

4/25/22



PATIENT

Max Calvo

SPECIES

Canine

BREED

Yorkshire Terrier

SEX

Male Intact

AGE

12 years

WEIGHT

17.2lbs

INTERPRETED BY

Maggie Machen Lamy, DVM
 DACVIM (Cardiology)

IMAGING PERFORMED BY

Pamela Harrigan, RDCS

HOSPITAL NAME

East Boston Animal Hospital

REFERRING VET

Dr. Chopra

INVOICE

23842

DATE

4/25/22

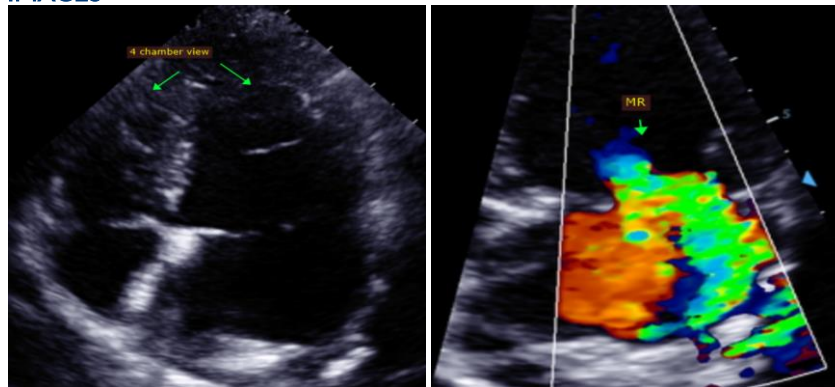
alfaxalone induction, isoflurane gas) are recommended. Pre-oxygenate for 5-10 minutes prior to induction. Monitor for arrhythmias, hypotension, and hypoxia both intra and post-operatively and intervene as necessary. Mild IV fluid restriction is recommended to avoid fluid overload. Avoid heart rate stimulating drugs such as atropine unless clinically indicated.

- Monitor for development of a cough, labored breathing, exercise intolerance or collapse episodes.

PLAN

- Recommend conservative monitoring with a recheck echocardiogram in 6 months, sooner if any development of clinical signs.

IMAGES



The information and recommendations provided are based on the images presented by the referring veterinarian. No evaluation can be communicated regarding pathology that was not visible in the image/video clips provided.

Thank you for this referral. This report was generated using transcription software, and minor dictation errors may be present. If the clinical or image interpretation does not parallel your findings or if I can be of any further assistance, please contact me.

Maggie Machen Lamy, DVM
 Diplomat of the American College of Veterinary Internal Medicine (Cardiology)
 info@sonopath.com